

Meningiomas

Meningiomas are a complex group of central nervous system tumours that originate from the dural covering of the brain or spinal cord. Although generally benign, a small percentage is locally aggressive, and an even rarer form of meningioma is malignant. It can arise from anywhere in the brain where there is meningeal cover. A third are found at the brain surface (**convexity**), a third near the surface, but attached to sagittal sinus and falx (**parasagittal / falcine**). The remaining are found at the **skull base**, and are most challenging to treat.

Clinical presentation is very diversified depending on its location and rate of growth. For example, a right frontal convexity meningioma can reach mammoth size before it produces features of frontal lobe syndrome and raised intracranial pressure. Whereas a small meningioma in the cavernous sinus can raise suspicion by causing cranial neuropathies such as double vision or facial pain.

Diagnosis poses no problem provided that the clinician has a high index of suspicion. MRI before and after contrast is the single most useful diagnostic imaging modality. CT may add more information for calcifications and bony anatomy. Catheter angiography is no longer necessary, except for pre-op embolisation to decrease its vascularity.

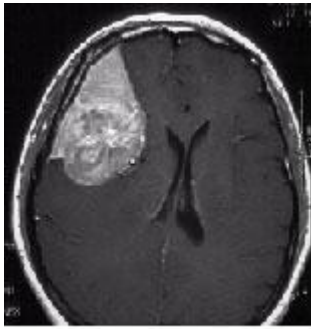
Treatment must be individualised for each patient:

1. No Treatment

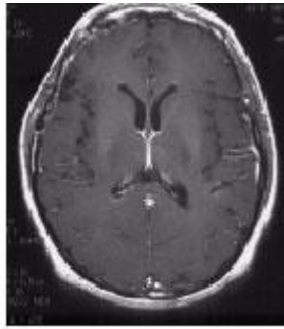
For small meningiomas found incidentally in the elderly lady with no mass effect or tumour activity, it is best left alone or observed sequentially with MRI.

2. Open Surgery

Convexity meningiomas are best treated by surgical resection which must include its dural base. Parasagittal meningiomas at the anterior third are likewise resected in total. Open surgery no doubt is the treatment of choice for these lesions. Yet, sometimes its attachment to the sinus may not be radically resected without causing damage to vital draining veins (especially for posterior 2/3 parasagittal meningiomas). Such residual dural base can either be left to observation or second stage Gamma Surgery.



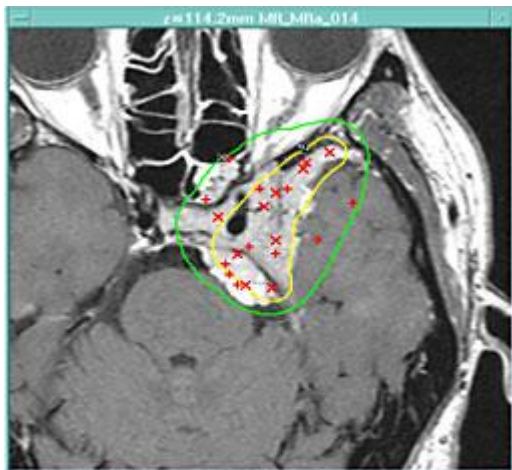Large convexity meningioma



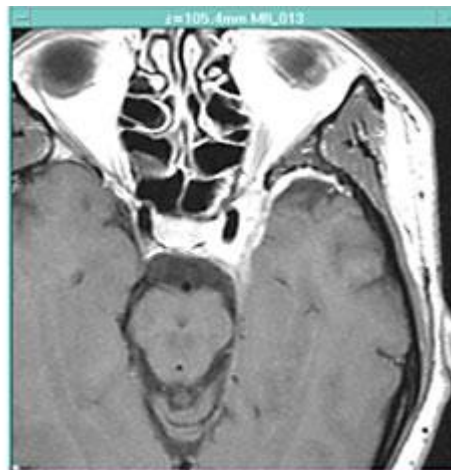
18 months after surgery

3. Open Surgery Plus Gamma Surgery

Large skull base meningiomas especially those at the middle and posterior cranial fossa are notoriously difficult to resect in total without creating devastating neurological deficits. The best strategy will be (I) Resect as much as possible to nullify mass effect and relief optic-chiasmal compression; (II) Treat residual small volume remnant attached to bone, cavernous sinus, carotid artery, venous sinuses with Gamma Surgery at a later date. Such approach provides the best long term functional outcome.



Combined microsurgery + Gamma Surgery
for parasellar meningioma



>70% shrinkage 1 year later

4. Gamma Surgery Alone

Gamma Surgery provides excellent symptom and tumour control **for small volume skull base meningiomas**. For an elderly lady suffering from concurrent medical problems harbouring a cavernous sinus meningioma presenting as 6th palsy, Gamma Surgery may be the ideal treatment with zero mortality and near zero morbidity, while achieving >90% chance of tumour shrinkage and relieve of symptoms.