

## **Pituitary Tumours and Craniopharyngiomas**

Pituitary tumours are a diversified group of adenomas arising from the pituitary gland. The endocrine active adenomas usually cause symptoms when they are quite small (microadenoma), by virtue of excessive hormonal productions. The most common ones are prolactinomas. They cause menstrual disturbances and spontaneous milk discharge in women, or rarely, impotence in men by excessive production of prolactin. In acromegaly, the affected patient has features of excessive growth hormone production that are instantly recognizable. Both prolactinomas and growth hormone adenomas are not difficult to diagnose: good clinical suspicion, appropriate blood tests, and special MR studies of the pituitary region.

The non-functioning adenomas (endocrine inactive) cause symptoms when they are large (macroadenoma) and compressing onto the optic nerves and chiasm. Affected patients complain of poor visual acuity and in particular, poor peripheral vision. The alerted doctor will perform visual field tests which typically show loss of peripheral vision in the outer halves: bitemporal hemianopsia. Blood tests may not reveal abnormalities unless the tumour is very large or just bled. Bleeding inside such adenoma is not an uncommon presentation: the patient will experience sudden headache followed by tunnel vision and blindness. Coma may ensue from acute hypo-pituitarism. Diagnosis, although sounds straightforward, is often delayed. Lack of physician awareness may be the reason. Generally, an alerted physician, bedside visual tests, and a plain lateral skull radiograph may hint at the diagnosis. Naturally, MRI of the pituitary is the best imaging modality. Very rarely, one may encounter an aneurysm in this region which mimicks a pituitary macroadenoma. Careful analysis of the MRI with or without further MRA studies will settle the issue with no difficulty.

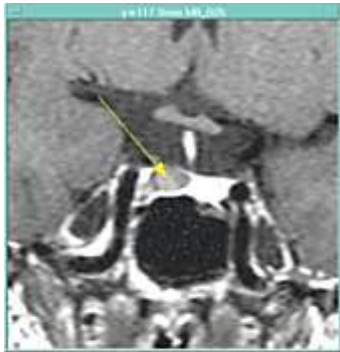Treatment of pituitary adenomas will depend on:

1. Whether it is endocrine active; if yes, which hormone is incriminated.
2. Size, extension in either or all of the 4 directions: superiorly, to compress the optic nerves, inferior to the nose (sphenoid sinus), laterally to the cavernous sinuses, or posteriorly to compress the normal pituitary gland.

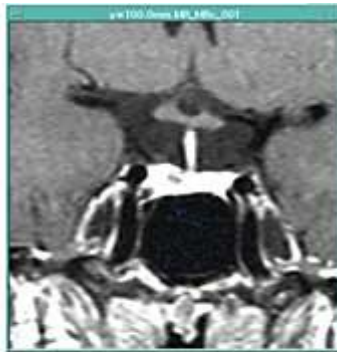Medical therapy (anti-prolactin) is the treatment of choice for prolactinomas.

Bromocryptine or its analogues, works in >90% of cases. Only when patients are truly intolerant of side effects of medication, or when adequate medical therapy fails to control the tumour, then one resorts to surgery. Transsphenoidal removal of the tumour uses to be the procedure of choice. In expert hands, it offers hopes of cure with very little

morbidity. Yet, more than one third of tumours recur within 10 years of surgery, rendering surgery less than ideal for ultimate cure. Gamma Surgery has recently been used as second or third line treatment when medication and or surgery fails. Preliminary results are encouraging.



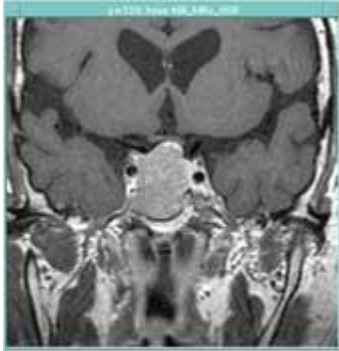
Prolactinoma not responding to Bromocriptine therapy



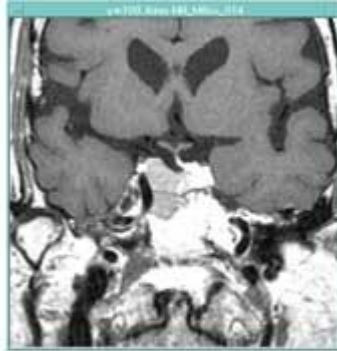
Excellent shrinkage with normalised prolactin 1 year after Gamma Surgery

Growth hormone producing adenomas are notoriously difficult to eradicate. Acromegalics have shortened longevity from heart, liver, or other complications of excessive growth hormone activity. Medical treatment (growth hormone antagonist) is not as effective as in the case of prolactinomas. Transsphenoidal surgery, although very useful, may not completely eradicate tumour and thus normalize growth hormone level. Fractionated radiotherapy used to be the only effective adjuvant therapy besides medications and surgery. Fractionated radiotherapy, however, may not have its desired effect until several years later. It also causes permanent pituitary hypofunction in about 40% of patients. Around 3% of patients develop radiation induced tumours in the radiation field 10 to 15 years later. Gamma Surgery has been used instead of radiotherapy in many centres specialising in pituitary tumours with good results. More long term follow up will establish its role in treatment of acromegaly. Recent research suggests that anti-growth hormone treatment may have radio-protective effect on the tumour rendering it more radio-resistant to Gamma Surgery. Stopping medications for 3 months before Gamma Surgery may produce the best results.

For non-functioning adenomas large enough to cause visual symptoms, transsphenoidal surgery provides rapid relief of symptoms. In many cases, it is the only treatment that is required. In cases where the tumour is very large, transcranial surgery may be necessary. Yet, repeated surgery may still leave tumours behind, particularly when there is cavernous sinus invasion. Recurrence then is high. Again, fractionated radiotherapy used to be the only available adjuvant therapy. Gamma Surgery is now being used increasingly to eradicate residual or recurrent tumour, even after radiotherapy.



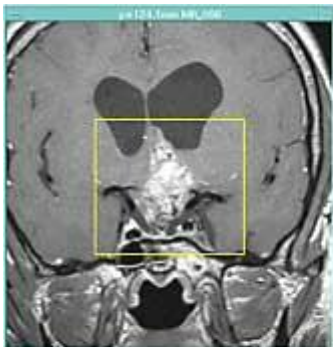
Large non-functioning adenoma



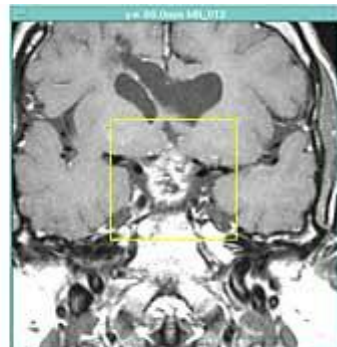
Excellent shrinkage 1 year after Gamma Surgery

To summarize, pituitary adenomas are basically benign tumours that can be cured. It is perfectly legitimate from the patient's perspective to expect good long term outcome and quick return to normal life. Yet, it is such a diversified, complex, and potentially dangerous lesion that no single treatment modality can claim superiority. Except for the small incidental adenomas that are asymptomatic, pituitary adenomas requires a multi-disciplinary approach to effect a cure while avoiding complications. The marriage of microsurgery and Gamma Surgery appears promising.

Craniopharyngiomas are completely different tumours. They usually arise above the pituitary gland. They are generally benign tumours but are notoriously difficult to remove totally. Recurrence rate is high when total resection is not possible. Again, microsurgery plus Gamma Surgery prove to be a new and important partnership in the long term control of these difficult tumours.



Recurrent craniopharyngioma despite repeat surgery + radiotherapy



Significant shrinkage with better vision 1 year after Gamma Surgery